

Chapter 5

Airway/Breathing

Introduction

Rapid assessment and management of airway and ventilation are critical to preventing morbidity and mortality. Airway compromise can occur rapidly or slowly, and an airway may deteriorate after having been adequate in the initial assessment. Frequent reassessment is necessary. Preventable causes of death from airway problems in trauma include the following:

- Failure to recognize the need for an airway.
- Inability to establish an airway.
- Failure to recognize the incorrect placement of an airway.
- Displacement of a previously established airway.
- Failure to recognize the need for ventilation.
- Aspiration of the gastric contents.

Initial airway management at any level, but especially outside of medical treatment facilities, is crucial for the survival of casualties. The immediate goal is to move the tongue, pharyngeal soft tissues, and secretions out of airway. **Until a formal airway is established, place patients in the lateral or prone position (rescue position), unless cervical spine precautions are appropriate in the particular battlefield situation.**

- Chin-lift and head tilt.
 - Place fingers under the tip of the mandible to lift the chin outward from face.
- Two-handed jaw thrust.
 - Place both hands behind the angles of the mandible and displace forward. This method can be used on the patient with cervical injury.
- Oropharyngeal airway.
 - Estimate airway size by distance from corner of the mouth to the ear lobe.

- Insert oral airway upright if a tongue depressor is used (preferred method).
- Keep the airway inverted past the tongue, then rotate 180°.
- If the oropharyngeal airway is too small, it will not alleviate the obstruction. If the oropharyngeal airway is too long, it may fold the epiglottis caudally, worsening the obstruction.
- **Oral airways are not used in conscious patients.**
- Nasopharyngeal airway.
 - Pass lubricated nasal airway gently through one nostril.
 - Use with caution in significant facial/skull base fractures.
 - Is tolerated by conscious patients.
- Field expedient.
 - Pull tongue forward and safety pin or suture it to the corner of the mouth.
- Endotracheal intubation is preferred for transport in any unconscious/unstable patient.
- Cricothyrotomy.

Ventilation

- Ventilate patient with the bag-valve mask.
 - **Bring the face into the mask rather than pushing the mask onto the face.**
 - The chin lift and head tilt are also used during mask ventilation unless they are contraindicated due to cervical spine precautions.

Assess air movement during mask ventilation by observing the rise and fall of the chest, auscultation, absence of a mask leak, compliant feel of self-inflating bag, and stable oxygen saturation.

- If air movement is not achieved, use **two-person mask ventilation** (Fig. 5-1).
 - ◆ One person lifts the jaw aggressively at the angles of the mandible; the other holds the mask and ventilates. Alternatively, one person may lift and hold the mandible with both hands, while at the same time holding down the mask on both sides. The other person ventilates the patient.

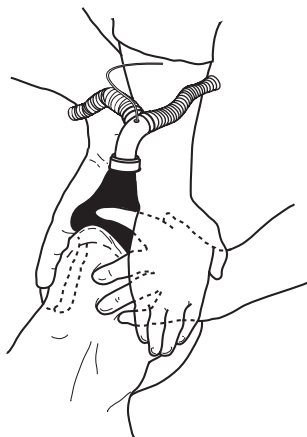


Fig. 5-1. Two-person mask ventilation.

- ◆ If air movement is still not present, obtain a definitive airway.
- Unsuccessful and aggressive attempts at ventilation may result in inflation of the stomach, placing the patient at increased risk for vomiting and aspiration.

Positive pressure ventilation can convert a simple pneumothorax into a tension pneumothorax.

Perform frequent assessment and have equipment available for needle chest decompression.

Orotracheal Intubation

"7-P" Mnemonic for Rapid Sequence Intubation (RSI)

1. **PREPARATION.** Pre-intubation preparation checklist (see RSI checklist in Chapter 8, Anesthesia).
2. **PREOXYGENATE** with 100% oxygen by mask.
3. **PRE-INTUBATION OPTIMIZATION.** Initiate appropriate damage control resuscitation (DCR).

4. **PARALYSIS INDUCTION.** Induction agent: ketamine 2 mg/kg IV/IO. Muscle relaxant: succinylcholine 1.0–1.5 mg/kg IV push (avoid in crush/burn injuries >24 h).
5. **PASS THE TUBE.** Laryngoscopy and orotracheal intubation.
6. **POST-PLACEMENT MANAGEMENT.** Verify tube placement.
7. **POST-INTUBATION SEDATION.**

Consider nasogastric (NG) or orogastric (OG) tube placement after securing airway.

- Direct laryngoscopy technique.
 - Ensure optimal “sniffing” position is achieved unless contraindicated by cervical spine injury.
 - Open the mouth by scissoring the right thumb and middle finger.
 - Hold the laryngoscope in the left hand and insert the blade along the right side of the mouth, slightly displacing the tongue to the left.
 - ◆ **Macintosh** (curved) blade: Advance the tip of the blade into the space between the base of the tongue and the epiglottis (ie, into the vallecula). Apply force at a 30°–45° angle, lifting the entire laryngoscope/blade without rocking it backward (Fig. 5-2).

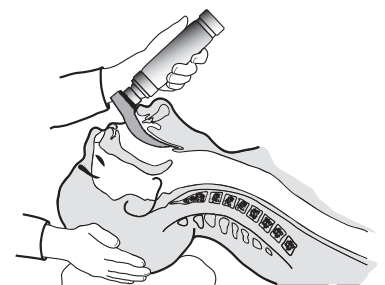


Fig. 5-2. Use of curved blade laryngoscope.

- ◆ **Miller** (straight) blade: Advance the tip of the blade into the posterior oropharynx, picking up the epiglottis and tongue base anteriorly and laterally, and apply a force vector like that of the Macintosh blade. Avoid rocking the laryngoscope backward (Fig. 5-3).

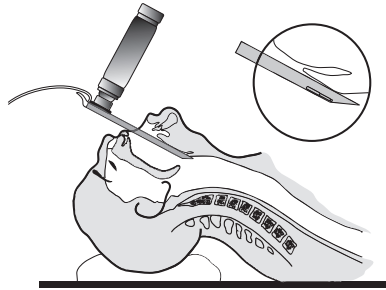


Fig. 5-3. Use of straight blade laryngoscope.

- Visualize the vocal cords.
- Consider the “BURP” (Backward Upward Rightward Pressure) maneuver when the laryngoscopic view is poor (Fig. 5-4).

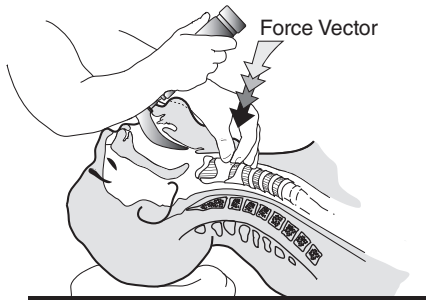


Fig. 5-4. BURP (Backward Upward Rightward Pressure) maneuver.

- ◆ “BURP” of the larynx was also referred to as external laryngeal manipulation.
- ◆ Place the fingers of an assistant onto the larynx with your right hand and manipulate the glottic opening into the field of view.

- ◆ Assistant then holds the position for intubation.
- **Eschmann stylet** or Gum Elastic Bougie (Fig. 5-5).

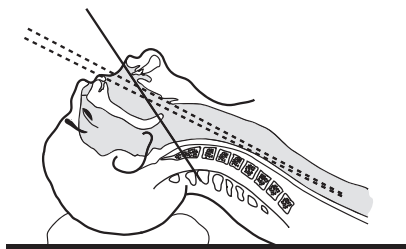


Fig. 5-5. Eschmann stylet in place.

- ◆ Blindly guide the tip of the stylet beneath the epiglottis, then anteriorly through the vocal cords.
- ◆ Advance the bougie deeply. Placement into the trachea results in the sensation of tracheal ring “clicks” and turning of the stylet as it passes airway bifurcations.
- ◆ The patient may cough as the stylet passes through the airway.
- ◆ When passed beyond the trachea, the stylet will stop at a terminal bronchus. If placed into the esophagus, it will pass indefinitely into the stomach without any tactile feedback.
- ◆ The endotracheal tube (ETT) is guided over the stylet into the airway, and tracheal intubation is confirmed.
- Advance the ETT between the vocal cords, withdraw stylet, and advance the ETT to 20–21 cm at the teeth for adult females and 22–23 cm for adult males. Deeper placement may result in right mainstem intubation.
- Confirm placement of the ETT in the trachea.
- Auscultate over the axilla to ensure that breath sounds are equal.

Avoid making more than three attempts at direct laryngoscopy. Excessive attempts may result in airway trauma and swelling, potentially turning a “cannot intubate” urgency into a “cannot intubate–cannot ventilate” emergency.

Difficult Airway

After three unsuccessful attempts at direct laryngoscopy, abandon the technique and try alternatives.

- Alternative intubation techniques.
 - Video-assisted laryngoscopy (GlideScope Ranger) is currently a key tool.
 - Gum elastic bougie. Visualize epiglottis, pass inferior and anterior, feel for tracheal rings, hard stop/diversion at carina. If in esophagus should be bottomless soft feel. Pass tube over bougie once in trachea. If resistance at arytenoids, slightly withdraw, rotate ETT, and pass tube gently.

Do NOT use gum elastic bougie in penetrating upper airway trauma or central airway obstruction (foreign body).

- Alternative (extraglottic) airways.
 - ◆ May NOT be definitive airways.
 - ◆ Allow for oxygenation and ventilation when standard airways cannot be placed.
 - ◆ Supraglottic airways.
 - ◇ laryngeal mask airway (LMA)
 - ◇ iGEL
 - ◆ Retroglottic airways.
 - ◇ King LT
 - ◇ Combitube
- Perform a surgical airway.

Surgical Cricothyrotomy

- Identify cricothyroid membrane (between cricoid ring and thyroid cartilage [Fig. 5-6a]).
- Prep skin widely.
- Grasp and hold trachea until airway is completely in place.
- Make a **vertical SKIN** incision down to the cricothyroid membrane (a no. 10 or no. 11 blade).
- Bluntly dissect the tissues to expose the membrane.
- Make a **horizontal MEMBRANE** incision (Fig. 5-6b).
- Open the membrane with forceps or the scalpel handle.
- Insert a small, cuffed ETT, 6.0–7.0 inner diameter, to just above the balloon (Fig. 5-6c).

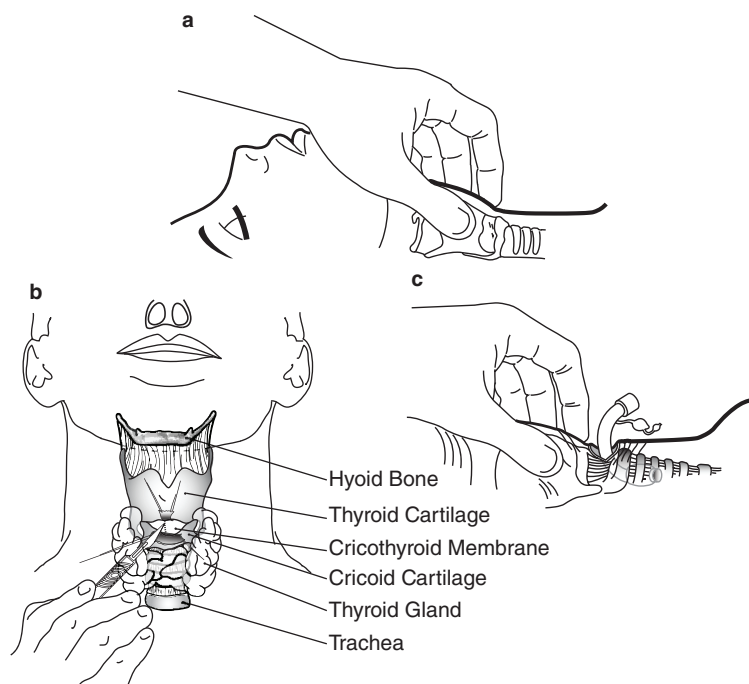


Fig. 5-6. Steps of surgical cricothyrotomy. (a) Identify cricothyroid membrane. (b) Make a horizontal membrane incision. (c) Insert a small, cuffed ETT to just above the balloon.

- Confirm tracheal intubation.
- Suture the ETT in place and secure it with ties that pass around the neck.

Laryngeal Mask Airway

- Insert blindly without a laryngoscope. The laryngeal mask airway (LMA) rests over the laryngeal inlet.
- Compared to an ETT, the LMA supports less airway pressures and offers less aspiration protection.
- Check the LMA cuff, then deflate it until the down side (inner) surface is smooth and flat; lubricate the pharyngeal (upper) side of the LMA.
- The sniffing position works best, but the LMA may be inserted in different patient positions.

- Insert LMA (3–4 for women, 4–5 for men) with upper (pharyngeal) side **gliding along the hard palate, down and around into the posterior pharynx**. This allows proper direction and reduces the chance of cuff folding.
- Do **NOT** push the LMA directly back into the mouth. This folds the cuff and prohibits proper placement.
- Inflate cuff with 20–30 cc of air via syringe. Slight upward movement of the LMA tubing is seen.
- Secure the LMA.

King LT Insertion

- Place patient in sniffing position and introduce the King tube blindly into the corner of the mouth.
- Gently advance the tube until base of connector is aligned with the teeth.
- Inflate the cuff according to the volume noted on tube.
- Attach ambu bag. While gently bagging, slowly withdraw tube until ventilation is easy and free flowing with minimal airway pressure and use tube confirmation measures.

**For Clinical Practice Guidelines, go to
http://jts.amedd.army.mil/index.cfm/PI_CPGs/cpgs**

